

◆ EXPERIMENTAL INVESTIGATION ◆

Implant Degradation and Poor Healing After Endovascular Repair of Abdominal Aortic Aneurysms: An Analysis of Explanted Stent-Grafts

Annie Major, BS¹; Robert Guidoin, PhD²; Gilles Soulez, MD, MSc¹; Louis A. Gaboury, MD¹; Guy Cloutier, PhD¹; Marc Sapoval, MD³; Yvan Douville, MD²; Guy Dionne, MD²; Robert H. Geelkerken, MD⁴; Paul Petrasek, MD⁵; and Sophie Lerouge, PhD¹

¹Centre Hospitalier de l'Université de Montréal (CHUM), Montreal, Qc, Canada.

²Department of Surgery, Université Laval, Québec, Canada. ³Service de Radiologie Cardiovasculaire, Hôpital Européen Georges Pompidou, Paris, France. ⁴Department of Vascular Surgery, Medische Spectrum Twente, Enschede, The Netherlands. ⁵Division of Vascular Surgery, Peter Lougheed Centre, Calgary, Alberta, Canada.

◆ ————— ◆
Purpose: To study explanted stent-grafts to achieve a better understanding of the mechanisms of failure after endovascular treatment of abdominal aortic aneurysms (AAA).

Methods: Twelve stent-grafts were harvested at autopsy (n=3) or during surgical conversion (n=9). Device alterations were investigated by macroscopic examination, radiography, and surface analysis techniques. Healing around the implants was studied via histology and immunohistochemistry, with particular attention to the stent-graft/tissue interface.

Results: Degradation was more important with Vanguard stent-grafts (off the market) than with AneuRx and Talent stent-grafts, but rupture of nitinol wires and poor surface finish in Talent stent-grafts raise concern about their corrosion resistance and long-term stability. Poor healing was observed around stent-grafts even after several years of implantation, with absence of vascular smooth muscle cells, fibroblasts, and collagen formation. In addition to the well-known foreign body reaction around the graft, numerous polymorphonuclear cells characteristic of the first step of healing were present in tissues around stent-grafts retrieved at surgical conversion. Factors explaining the lack of tissue organization around stent-grafts are discussed.

Conclusion: The long-term stability of implants remains a concern and requires more transparency from manufacturers regarding the surface properties of their devices. Lack of neointima formation impairs biological fixation of the implant to the vessel wall, leading to possible endoleaks and migration. New-generation stent-grafts promoting biological fixation should be developed to improve clinical outcomes of this minimally invasive treatment.

J Endovasc Ther 2006;13:457-467

◆ ————— ◆
Key words: stent-graft, abdominal aortic aneurysm, explants, vascular healing, implant degradation, endovascular aneurysm repair, nitinol, corrosion, healing, neointima

◆ ————— ◆
This project was funded by the Heart and Stroke Foundation of Canada (HSFC), the Natural Sciences & Engineering Research Council of Canada (NSERC), Valorisation-Recherche Québec (Group Grant No. 2200-094), and research scholarship awards from the Fonds de la Recherche en Santé du Québec (FRSQ) (S.L., G.S., G.C.).

Gilles Soulez received a grant from Medtronic for another project, R.H. Geelkerken is proctor for Medtronic AVE in The Netherlands, and Robert Guidoin received grants and/or contracts from Boston Scientific, Medtronic, and Vascutek-Terumo for other projects. These companies were not involved in this study. The other authors have no commercial, proprietary, or financial interest in any products or companies described in this article.

Address for correspondence and reprints: Sophie Lerouge, PhD, Laboratoire de biomatériaux endovasculaires (LBeV), CHUM Research Center, Hôpital Notre-Dame, JA de Sève Building, room Y-1603, 1560 Sherbrooke St. East, Montreal, Qc, H2L 4M1 Canada. Fax: 1-514-412-7785; E-mail: sophie.lerouge@umontreal.ca

Endovascular aneurysm repair (EVAR) has numerous advantages over open surgery, including shorter patient recovery and hospitalization time, less blood loss, and, as recently demonstrated, lower rates of mortality/morbidity after 1 month.¹⁻³ However, efficacy is still jeopardized by several complications, including stent-graft migration^{4,5} and persistence of blood flow into the aneurysm (i.e., endoleak).⁶⁻⁸ These complications are associated with a higher risk of aneurysm rupture and call for secondary endovascular interventions, which are performed in 12% to 28% of cases.⁹

The mechanisms leading to these complications are complex and still poorly understood. Mechanical factors related to inadequate design, poor fatigue resistance, or in vivo degradation of the implant have been documented.^{10,11} Some studies have reported poor biological incorporation of stent-grafts into the parent vessel,^{12,13} but to our knowledge, histopathological analysis of stent-graft/tissue interface from explants has been done only on a first-generation custom-made stent-graft.¹²

Retrieval programs by manufacturers have led to the development of new-generation implants.¹⁴ However, analysis of explanted stent-grafts by independent researchers is also essential to identify the Achilles' heel of commercially manufactured stent-grafts. These data give insights into the in vivo adaptation of these endoprostheses to help define strategies for improving short and long-term clinical outcomes of this treatment. We report here the analysis of explanted stent-grafts harvested at autopsy or surgical conversion, and we discuss the importance of each factor as regards clinical success or failure following EVAR. Particular attention was given to the stent-graft/tissue interface.

METHODS

Patient Source

Twelve aortic stent-grafts explanted at autopsy (n=3) or during late surgical conversion to open repair (n=9) were included in this study, which was approved by the local institutional ethics committee. These stent-grafts had

been implanted in 11 men and 1 woman (mean age 73 years, range 56-87) for the treatment of abdominal aortic aneurysms (AAA) between 1997 and 2002, with an average period of implantation of 28 months (1.5-50). The retrieved stent-grafts included 2 AneuRx (Medtronic Vascular, Santa Rosa, CA, USA), 5 Talent (Medtronic Vascular), and 5 Vanguard (Boston Scientific, Natick, MA, USA). All had nitinol structures fixed to a polyester graft with polypropylene or polyester sutures, but their design differed (Fig. 1). In 2 autopsy cases (AneuRx), patient death was unrelated to EVAR; the third stent-graft (Vanguard generation II) was obtained after occlusion of the right limb. Three surgical conversions (Table 1) were performed after aneurysm rupture.

Specimens harvested after autopsy were retrieved en bloc, with the complete aneurysm (aneurysm sac, stent-graft, and thrombus surrounding the stent-graft), including the proximal and distal landing zone of the stent-graft in the abdominal aorta and the common iliac arteries. After retrieval, the specimens were fixed in formalin and sent to our laboratory with available clinical and in vivo imaging data.

Non-Destructive Testing

Specimens were submitted to non-destructive analysis, including gross evaluation of the amount, aspect, and fixation of tissues surrounding the implant. The morphology and integrity of the metallic structure, as well as the graft and sutures, were observed under stereomicroscopy. Ex vivo radiography was performed to examine the metallic structure of the implants and its potential alteration.

Destructive Testing

Histology. The Exakt cutting-grinding system (Exakt GmbH, Norderstedt, Germany) was used to prepare 1- to 2-cm-thick macroscopic sections containing the implant. Once observed and photographed, these sections were used to prepare histological slides, which included the tissue/implant interface. Tissues were dehydrated, embedded in acrylic resin (Technovit 7200; Heraeus-Kulzer, Ar-

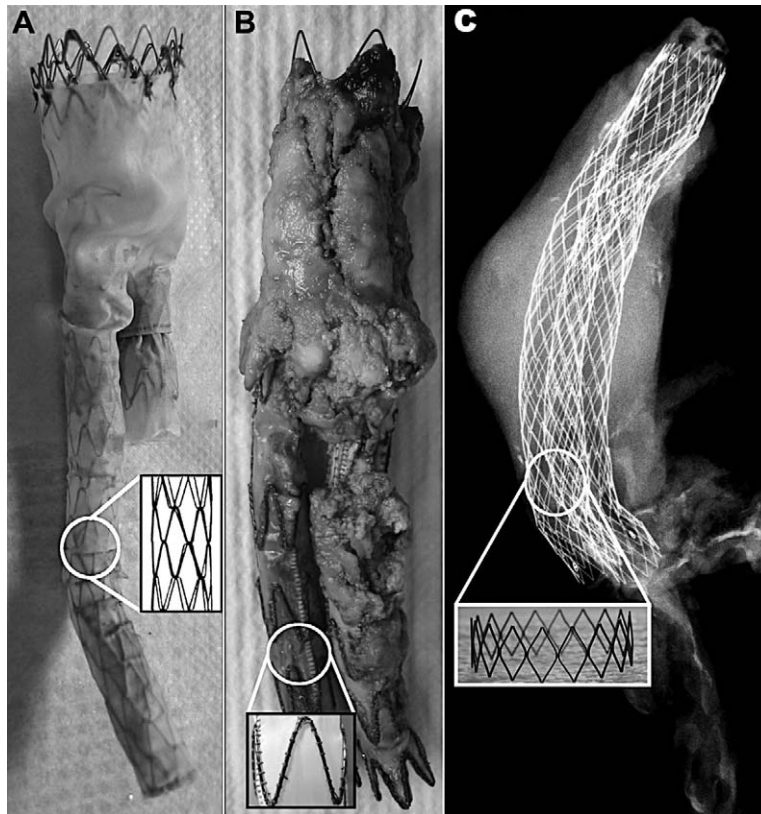


Figure 1 ♦ The 3 types of explanted stent-grafts and their macroscopic structure. **(A)** Vanguard stent-grafts were made of zigzag nitinol struts attached by polypropylene sutures and covered by a woven polyester graft. A bare stent was present at the proximal end of the implant to ensure better aortic fixation. The graft was made from yarns of microfilaments ($\phi=10\ \mu\text{m}$), regularly interlaced in ends and picks to produce a continuous sheath. **(B)** Talent stent-grafts were made of a monofilament polyester fabric (Dacron LPS prepared with $40\text{-}\mu\text{m}$ -diameter filaments) fixed by polyester suture to NiTi spring wires ($\phi=500\ \mu\text{m}$). NiTi wires were connected to each other by a longitudinal connecting bar, thus increasing the kinking resistance of the implant. The NiTi structure was located inside the graft at the proximal end and outside the graft at the limb. A bare stent was present at the proximal neck. **(C)** Radiograph of an AneuRx stent-graft retrieved with a complete aneurysm. AneuRx endografts had no bare stent. The polyester graft, similar to that of Vanguard devices, was supported by a square-shaped nitinol exoskeleton ($\sim 300\times 300\ \mu\text{m}$).

monk, NY, USA), cut, and polished into $30\text{-}\mu\text{m}$ sections that were then stained with hematoxylin and eosin. Finally, the implant was carefully removed from some transverse sections to prepare conventional $3\text{-}\mu\text{m}$ -thick paraffin-embedded slides. Masson trichrome and Von Kossa stains were used to detect collagen and calcium deposits. Gram and Periodic Acid Schiff (PAS) stains were used when infection was suspected to identify microorganisms. Immuno α -actin staining confirmed the pres-

ence of vascular smooth muscles cells (VSMC) or myofibroblasts.

Implant Surface Analysis. For surface analysis, parts of the devices were cleaned with a solution of 2% ZYMIT enzyme cleaner (Viasys Healthcare, Conshohocken, PA, USA) for 4 hours in an ultrasonic bath to remove all biological tissues. Samples were then immersed for 5 minutes in acetone and for 5 minutes in methanol before being dried. The composition and thickness of the oxide layer

TABLE 1
Patient Data

Age, y/Sex	Device	In Situ Time, mo	Source	Cause of Death/Surgery
1. 79/M	AneuRx	1.5	Autopsy	Paralytic ileus and severe melena
2. 75/M	AneuRx	27	Autopsy	Bronchopneumonia and sepsis
3. 74/M	Talent	24	Conversion	Stent-graft infection
4. 68/M	Talent	50	Conversion	Aneurysmal degeneration of the proximal neck
5. 75/M	Talent	14	Conversion	Type I distal endoleak, followed by AAA rupture
6. 77/M	Talent	30	Conversion	Type III endoleak, AAA enlargement
7. 56/F	Talent	27	Conversion	Type I endoleak, AAA rupture
8. 76/M	Vanguard (II)	2.5	Autopsy	Occlusion of the right limb, death occurred during conversion
9. 87/M	Vanguard (I)	18	Conversion	Type II endoleak, AAA rupture
10. 76/M	Vanguard (I)	48	Conversion	Type III endoleak, limb disconnection
11. 65/M	Vanguard (I)	40	Conversion	Pulsatile AAA, limb occlusion and displacement
12. 68/M	Vanguard (II)	25	Conversion	Limb occlusion, AAA enlargement and pulsation

AAA: abdominal aortic aneurysm.

of the nitinol struts were evaluated by Auger electron spectroscopy (AES) using a JAMP-30 spectrograph (JEOL, Peabody, MA, USA) to record survey spectra and depth profile, respectively, at 3 locations on each sample. Nickel (Ni) content at the surface was expressed as the superficial ratio of Ni to titanium (Ti). The thickness of the oxide layer was estimated by measuring sputtering time when oxygen reached half its maximum value. The thickness in terms of sputtering time was converted to depth units in nanometers using the sputtering rate calibrated for SiO₂.¹⁵ Specimens were gold-palladium-coated and observed by scanning electron microscopy

(SEM) in backscatter mode at a 15-kV accelerating voltage (S-3500, Hitachi Canada Ltd., Mississauga, On, Canada) for detection of microscopic surface alteration. One non-implanted control sample of each stent-graft was also examined for comparison.

RESULTS

All explanted stent-grafts showed device alterations on macroscopic analysis (Table 2). These alterations varied from fabric tearing (Fig. 2) to broken metallic struts (Fig. 3). Rupture of numerous ligatures between zigzag nitinol struts was generally observed on the

TABLE 2
Stent-Graft Alterations

Device	In Situ Time, mo	Graft Perforation	Broken Struts	Broken Sutures	Involvement of Implant Degradation in Clinically-Observed Complications
1 AneuRx	1.5	0	No	>3	—
2 AneuRx	27	0	No	2	—
3 Talent	24	3	1	>10	—
4 Talent	50	1	No	5	—
5 Talent	14	0	No	No	—
6 Talent	30	1	No	4	Type III endoleak due to hole in the graft
7 Talent	27	1	1	3	Massive type I endoleak and ruptured AAA related to fracture of a nitinol wire at apex
8 Vanguard	2.5	>10	>5	>10	—
9 Vanguard	18	8	No	>10	—
10 Vanguard	48	5	No	>10	Endoleak due to limb disconnection
11 Vanguard	40	6	>5	>10	Limb disconnection
12 Vanguard	25	3	No	5	—




Figure 2 ♦ Graft alterations observed on explanted stent-grafts. (A) Broken struts protruded through the graft in a Vanguard specimen. Holes in a Vanguard fabric (B) and in a Talent monofilament fabric (C), which led to type III endoleaks in vivo (case 6).

Vanguard prostheses. Rupture of several zig-zag struts was noted on 2 devices. Disconnection of the modular limb from the main body of the stent-graft was apparent in 2 cases of surgical conversion. In 4 of 5 explanted Vanguard specimens, implant degradation was directly or indirectly responsible for complications leading to surgical conversion.

Talent devices were generally less damaged than Vanguard explants despite similar mean

duration of implantation (27 and 29 months, respectively). However, in vivo implant degradation resulting in complications and surgical conversion occurred in 2 patients. AAA enlargement secondary to a hole in the fabric causing a type III endoleak was evident in the first patient (case 6, Fig. 2C). In the other (case 7), fatigue fracture of a spring wire at the proximal end (bare stent) elicited a type I leak complicated by AAA rupture 2 years after im-

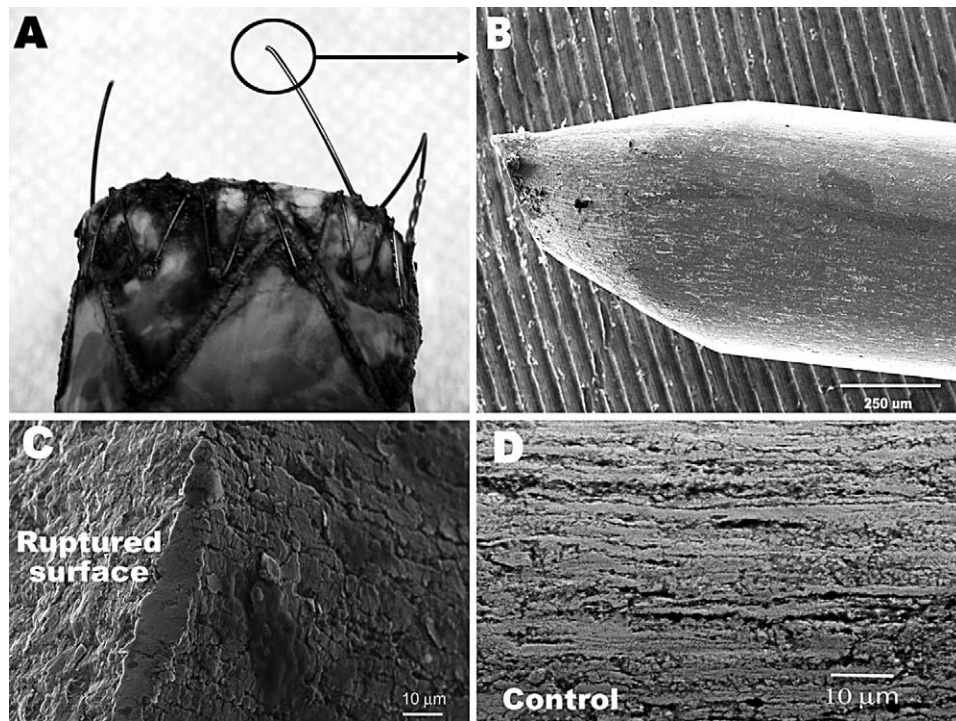


Figure 3 ♦ (A,B) Fractured nitinol strut at the apex of a Talent device, which led to massive type I leak. (C) Surface close to rupture showed corrosion (SEM). (D) A control (non-implanted) Talent stent-graft also showed numerous surface irregularities (SEM).

TABLE 3
Thickness and Nickel/Titanium (Ni/Ti) Superficial Ratio of the Oxide Layer Covering Nitinol Struts of Each Explant and Control Devices Determined by Auger Electron Spectroscopy

	Device	Oxide Layer Thickness, μm	Ni/Ti Superficial Ratio
1	AneuRx	0.02 \pm 0.01	0.3 \pm 0.3
2	AneuRx	0.02 \pm 0.01	0.1 \pm 0.1
3	Talent	0.11 \pm 0.01	0.4 \pm 0.2
4	Talent	0.24 \pm 0.01	0.4 \pm 0.3
5	Talent	0.22 \pm 0.01	0.4 \pm 0.1
6	Talent	0.21 \pm 0.01	0.3 \pm 0.2
7	Talent	0.22 \pm 0.01	0.5 \pm 0.2
8	Vanguard	0.23 \pm 0.01	0.4 \pm 0.1
9	Vanguard	0.16 \pm 0.02	0.1 \pm 0.1
10	Vanguard	0.17 \pm 0.01	0.1 \pm 0.1
11	Vanguard	0.17 \pm 0.02	0.1 \pm 0.1
12	Vanguard	0.17 \pm 0.01	0.2 \pm 0.2
Mean Values			
	AneuRx	0.02	0.2 \pm 0.2
	Talent	0.20	0.4 \pm 0.2
	Vanguard	0.18	0.2 \pm 0.1
Non-Implanted Devices*			
	Control AneuRx	0.13	0.1 \pm 0.1
	Control Talent	0.37	0.8 \pm 0.7
	Control Vanguard	0.12	0.3 \pm 0.1

* One each; these data are given for comparison, but their significance is limited.

plantation (Fig. 3B,C). In another Talent device (case 3), retrieved because of infection, several broken sutures and rupture of the nitinol longitudinal connecting bar were noted. Damage on AneuRx devices was limited to a few broken knots between metallic rings of the exoskeleton.

Surface Analysis of Metallic Frame

Under SEM, the nitinol struts of control and explanted AneuRx, Talent, and Vanguard devices presented numerous surface defects. Longitudinal grooves were observed on Talent stent-grafts, both explanted and control (Fig. 3D). Corrosion was visible in some areas, in particular those close to the ruptured surface of the large diameter NiTi struts on 2 Talent explants (Fig. 3C). AneuRx samples generally presented a smoother surface, except at borders where a very irregular surface was noticed.

As revealed by AES analysis, nitinol strut surfaces were composed of oxygen, titanium,

nickel, and some carbon due to contamination. Surface composition was non-uniform, with some regions exhibiting high Ni content at the surface, as expressed by the high Ni/Ti ratio (Table 3). AneuRx and Vanguard surfaces exhibited lower Ni/Ti ratios compared to Talent explants, where the Ni/Ti ratio rose to 1 in some areas. Significant Ni content was also observed on control sample surfaces. The thickness of the oxide layer was ~200 nm for explanted Talent and Vanguard stent-grafts and only 20 nm for explanted AneuRx samples (Table 3).

Healing Around Stent-Grafts

All endografts harvested during surgical conversion detached very easily from the native aortic wall and surrounding thrombus. Only small amounts of tissue were adherent enough to be removed with the stent-graft and processed for Exakt histological sections. More tissue remained attached on the metallic struts than on the Dacron grafts. In general,

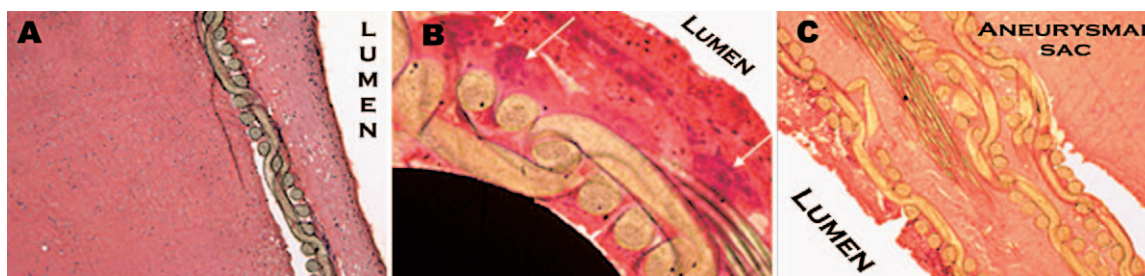


Figure 4 ♦ Typical deficient healing observed around explanted stent-grafts (hematoxylin and eosin). (A) Immature neointima with inflammatory cells around a Talent stent-graft retrieved at 2.5 years. Myointimal cells were absent. The aneurysmal sac was filled with amorphous thrombus. (B) Grafts were lined with foreign body giant cells (white arrows). (C) Graft infolding due to oversizing was commonly seen with Talent devices.

the luminal side of the grafts was not covered completely by a thin, translucent, and friable pseudoneointimal layer ranging from 30 to 500 μm . Histological analysis (Fig. 4) disclosed that all tissue encapsulating the stent-graft was unorganized thrombus, composed mainly of fibrin and phantoms of red blood cells (RBC). Absent were VSMCs, fibroblasts, and collagen, which are necessary for biological incorporation of the textile arterial substitutes. Endothelialization was not seen on the endoluminal side of any specimen. On the other hand, inflammatory cells were quite numerous. Dacron graft fibers were lined with many multinucleated giant cells and macrophages, indicative of a foreign body reaction (Fig. 4B), as reported after implantation of polyester vascular grafts and stent-grafts.^{12,16} In addition, polymorphonuclear cells (PMN), monocytes, and macrophages were disseminated throughout the thrombus, their numbers increasing near the lumen (Fig. 4A). Interestingly, PMNs were still numerous 4 years after implantation, a sign of persistent, acute inflammation. No evidence of chronic inflammation was noted.

In 1 patient (case 3), an extensive inflammatory process related to graft infection by gram-positive bacteria was observed. PAS and gram staining confirmed the presence of large clusters of microorganisms on histological examination, and blood culture before surgical conversion was positive.

The aneurysm walls of specimens harvested en bloc after autopsy presented features typical of medial and adventitial degeneration. At both necks, the implant was apposed

to an atherosclerotic vessel wall composed of calcification, cholesterol clefts, and an acellular fibrous capsule. No sign of an organized thrombus was found around the implant, the thrombus being mainly composed of fibrin, RBCs, and a few inflammatory cells. Multilayering of dense fibrin and RBC areas into Zahn lines or circular spaces was recorded, corresponding to the successive layers of thrombus formed with time.¹⁷

Two of the 3 autopsy cases (cases 8 and 2), harvested at 2.5 and 27 months, respectively, presented deficient healing similar to the findings in failed implants retrieved at surgery. These stent-grafts were encapsulated in unorganized thrombotic material. At the proximal and distal necks, poor apposition was noticed between the implant and the atherosclerotic wall, partly due to graft infolding (Fig. 5A,B). Even when the graft was well apposed to the vessel wall, a perigraft space of thrombotic material persisted between them (Fig. 5C). More than 2 years after implantation, no sign of stent-graft incorporation could be observed, even at the extremities of the implant.

The last necropsy specimen (case 1), harvested 6 weeks after implantation, showed a different pattern. Macroscopically, a thicker internal capsule and better stent-graft fixation into the aortic and iliac vessel walls was observed. Limited neointimal organization by myointimal cells, restricted to the luminal side, was clearly seen at the distal neck (Fig. 6). The origin of these cells (cell migration from the distal neck or circulating progenitor cells) is unknown. Endothelial cells were not

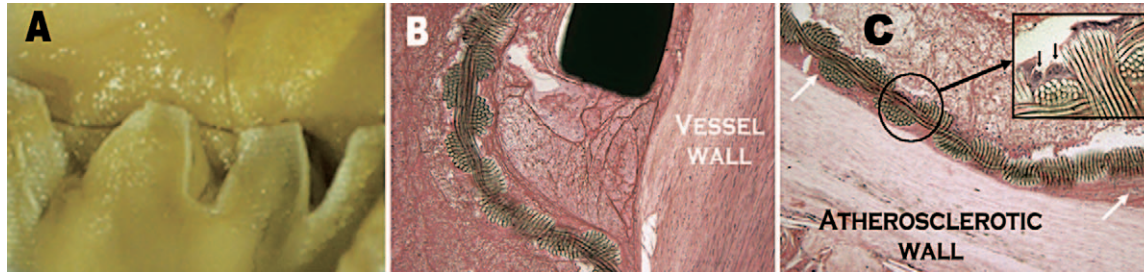


Figure 5 ♦ Stent-graft design does not favor biological incorporation into the vessel wall. (A) Macroscopic view of the abrupt junction between the aortic wall and the proximal end of an AneuRx stent-graft. (B) Graft infolding, which prevents good apposition to the vessel wall, was observed on many stent-grafts, especially the AneuRx and Talent devices (hematoxylin and eosin). (C) Even when the graft was in close apposition to the atherosclerotic wall, a film of thrombotic material persisted between them (perigraft, white arrows; hematoxylin and eosin). Multinucleated giant foreign body cells lined the graft (inset).

evident on histology or SEM, but it should be acknowledged that they could have been removed during dissection or while processing the samples.

DISCUSSION

Device-Related Complications and Failures

Severe *in vivo* alterations have been observed on first-generation implants.^{10,11,18} Since then, implants with better designs and mechanical and corrosion resistance have been developed, with increased kink resistance and structural stability. However, device-related complications and failures are still common. The extent of damage on Vanguard explants was relatively expected since

this second-generation implant has been removed from the market because of lack of structural stability (see Fig. 1). The rupture of numerous ligatures between struts can lead to decreased stent-graft kinking resistance, possible strut protrusion through the fabric, and, eventually, limb occlusion as seen on several Vanguard specimens. Although it is not possible to assess its impact, the endovascular procedure itself may be implicated in alterations observed with the Vanguard. Particularly in patient 8, from whom the stent-graft was harvested a mere 2.5 months after implantation, the numerous alterations of the device could be related to a long and difficult endovascular procedure with several stents.

AneuRx and Talent devices are still commercially available worldwide.¹⁹ In different

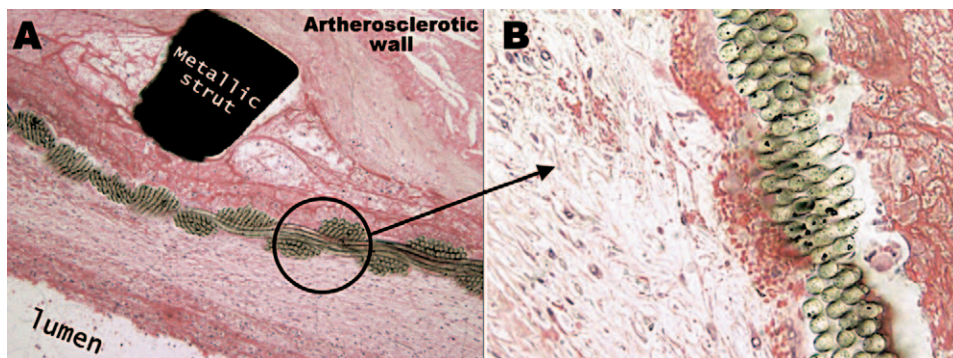


Figure 6 ♦ (A) Beginning of neointimal organization close to the iliac distal neck in a 6-week-old implanted AneuRx device. (B) Note that myointimal cells are restricted to the luminal side of the implant (hematoxylin and eosin).

clinical studies, they were associated with lower incidences of migration, kinking, limb occlusion, and secondary intervention compared to the Vanguard device.¹⁹ Yet, we report here 2 cases where surgical conversion was due to the failure of Talent stent-grafts. The fractures of large-diameter stent spring wires (~500- μ m diameter) observed in 2 Talent explants are not isolated cases. Thirty-four connecting bar fractures and 9 stents spring fractures have been reported worldwide on Talent stent-grafts.¹⁴ Since fatigue fractures are usually initiated at surface heterogeneities, they could be related to the surface irregularities and Ni content, which were apparent on explanted and also on non-implanted Talent devices.

Theoretically, the oxide layer covering the nitinol surface is mainly composed of titanium oxide, which confers good uniform resistance to corrosion of the alloy. All explanted stent-grafts, as well as the individual Talent and Vanguard controls we studied, also revealed significant amounts of nickel oxides in some areas. The surface composition, homogeneity, and thickness of the protective oxide layer strongly depends on industrial passivation processes, such as chemical etching or electropolishing.^{15,19,20} The differences observed between AneuRx, Talent, and Vanguard reflect the different surface treatments applied to each device. Heat-setting treatments, commonly used to predefine the shape of nitinol wires, such as Talent spring wires, have been shown to have very detrimental effects on corrosion resistance, which cannot be salvaged with subsequent surface treatments.²¹ This could explain the inhomogeneity and thickness of the oxide layer, including the high Ni level, observed on Talent stent-grafts. To avoid further strut fractures, a new Talent device was introduced in 2003, with a modified design (medial and not lateral connecting bar) and a new passivation technique by chemical etching.¹⁴ One can only hope that these modifications have improved the corrosion resistance and endurance of Talent devices.

For obvious reasons, industrial passivation techniques of commercial devices are not in the public domain, thus limiting the surgeons' knowledge of their aspects prior to clinical

use. Resistance to localized corrosion directly influences the amount of toxic Ni ions released, the risk of fracture, and long-term implant stability.²² Manufacturers should be urged to offer more information or provide samples for independent studies comparing commercially available devices. The discrepancy between the oxide layer thickness obtained on the explants and the controls, which is unlikely a consequence of implantation, highlights the difficulty of getting valid control samples produced at the same time as the explanted devices and with exactly the same processes and surface treatments.

In addition to the design and surface finish, biological factors could also influence the corrosion and in vivo stability of the device. The Talent device from case 3 showed severe alterations after 2 years of implantation (>10 ruptured sutures and 1 broken strut) and was retrieved due to infection. We could hypothesize that the large number of inflammatory cells releasing oxidative factors, such as free radicals, hydroperoxides, and reactive oxygen species, may have accelerated the degradation of the material, a phenomenon described as environmental stress cracking.²²

An Impaired Healing Process?

After its deployment into the aneurysm, a stent-graft is sandwiched by a thrombotic matrix. Its organization into a mature encapsulating "neointima" in continuation with the vessel wall would provide a good and permanent seal to completely exclude the aneurysm from blood flow and decrease the risks of stent-graft migration and endoleaks. Repair pathways activated after various forms of vascular injury usually lead to migration and accumulation of VSMCs and myofibroblasts derived from adventitial fibroblasts, which produce extracellular matrix components.^{23,24} When sustained chronically, this fibroproliferative process can even lead to pathological effects, such as restenosis after coronary stenting.²⁵ In contrast, neointima formation after EVAR is rather deficient.

This observation is in accord with previous studies documenting that stent-graft fixation to the vessel wall is mostly mechanical (i.e., due to radial forces exerted by the implant or

fixation hooks)¹³ and biological incorporation of the first-generation stent-grafts was deficient.¹² In our study, tissues retrieved around these stent-grafts at 18, 24, or 50 months showed characteristics of the first step of healing, which normally lasts a few days or weeks. PMNs should have been replaced long since by VSMCs and fibroblasts attracted by these cells to the injury site. Their presence 4 years after implantation is a sign of persisting insult and shows that tissue organization into a mature neointima has been impaired.

The cause of deficient neointima formation is not yet clear, but several factors could be involved, including AAA physiopathology and stent-graft properties. For one, the cellular characteristics of AAA may be implicated in suboptimal neointima formation. AAAs are characterized by thinning of the tunica media and strong depletion (~75%) of VSMCs due to increased apoptosis.^{26,27} The graft is not apposed to the vessel wall in the aneurysm sac, preventing direct colonization of the graft by cells coming from the aortic wall. Cells could migrate along the implant from the proximal or distal neck or derive from circulating progenitor cells, but graft design and surface properties are not favorable to cell migration and adhesion along the implant. Dacron and expanded polytetrafluoroethylene surface properties do not promote cell adhesion.²⁸ Moreover, their low porosity seems to limit cell invasion through the graft. We and others have indeed detected very little cellular invasion of grafts in human explants or in animal models.^{12,29}

The beginning of neointima formation, observed in one specimen, was restricted to the lumen surface of the graft. Although it is not certain that further incorporation would have taken place with time, this sample may be an example of good stent-graft incorporation. The reasons for the differences noted between this case and the complete lack of biological incorporation after 2 years with a similar AneuRx stent-graft (case 2) require further investigation.

Stent-graft design and mechanical properties may also play roles in deficient healing following EVAR, as underlined by the poor apposition observed between the implant and the atherosclerotic wall at proximal and distal

necks, in particular when graft infolding (commonly observed) is present.

Conclusion

Poor healing around stent-grafts raises concerns about the long-term outcomes of this minimally invasive procedure. The development of a new generation of stent-grafts with bioactive coating and VSMC therapy^{30,31} are promising strategies to improve healing.

Acknowledgments: The authors thank Drs. J-F Blair and S. Elkouri (CHUM), Dr. C.K. Zarins (Stanford University, CA, USA), and Dr. P. Julia (Paris, France), who provided some of the explants. We also thank Zhao Qin (CHUM) for the preparation of Exakt specimens; Annie Poirier, Eric Duchenes, and Stefania Polizu (École Polytechnique de Montréal) for their help with the AES and SEM experiments; and Cindy Charbonneau for linguistic revision of this article.

REFERENCES

1. Uflacker R, Robison J. Endovascular treatment of abdominal aortic aneurysms: a review. *Eur Radiol.* 2001;11:739-753.
2. Rutherford RB, Krupski WC. Current status of open versus endovascular stent-graft repair of abdominal aortic aneurysm. *J Vasc Surg.* 2004;39:1129-1139.
3. Greenhalgh RM, Brown LC, Kwong GP, et al. Comparison of endovascular aneurysm repair with open repair in patients with abdominal aortic aneurysm (EVAR trial 1), 30-day operative mortality results: randomised controlled trial. *Lancet.* 2004;364:843-848.
4. Mohan IV, Harris PL, van Marrewijk CJ, et al. Factors and forces influencing stent-graft migration after endovascular aortic aneurysm repair. *J Endovasc Ther.* 2002;9:748-755.
5. Kalliafas S, Albertini JA, Macierewicz J, et al. Stent-graft migration after endovascular repair of abdominal aortic aneurysm. *J Endovasc Ther.* 2002;9:743-747.
6. Elkouri S, Gloviczki P, McKusick MA, et al. Endovascular repair of abdominal aortic aneurysms: initial experience with 100 consecutive patients. *Mayo Clin Proc.* 2003;78:1234-1242.
7. Veith FJ, Baum RA, Ohki T, et al. Nature and significance of endoleaks and endotension: summary of opinions expressed at an international conference. *J Vasc Surg.* 2002;35:1029-1038.
8. Schurink GW, Aarts NJ, van Bockel JH. Endo-

- leak after stent-graft treatment of abdominal aortic aneurysm: a meta analysis of clinical studies. *Br J Surg*. 1999;86:581-587.
9. Becquemin JP, Kelley L, Zubilewicz T, et al. Outcomes of secondary interventions after abdominal aortic aneurysm endovascular repair. *J Vasc Surg*. 2004;39:298-305.
 10. Chakfe N, Dieval F, Riepe G, et al. Influence of the textile structure on the degradation of explanted aortic endoprostheses. *Eur J Vasc Endovasc Surg*. 2004;27:33-41.
 11. Guidoin R, Marois Y, Douville Y, et al. First-generation aortic endografts: analysis of explanted Stentor devices from the EUROSTAR registry. *J Endovasc Ther*. 2000;7:105-122.
 12. Malina M, Brunkwall J, Ivancev K, et al. Endovascular healing is inadequate for fixation of Dacron stent-graft in human aortoiliac vessels. *Eur J Vasc Endovasc Surg*. 2001;19:5-11.
 13. McArthur C, Teodorescu V, Isen L, et al. Histopathological analysis of endovascular stent grafts from patients with aortic aneurysms: does healing occur? *J Vasc Surg*. 2001;33:733-738.
 14. Criado FJ, Clark NS, McKendrick C, et al. Update on the Talent LPS AAA stent graft: results with "enhanced Talent." *Semin Vasc Surg*. 2003;16:158-165.
 15. Thierry B, Tabrizian M, Trepanier C, et al. Effect of surface treatment and sterilization processes on the corrosion behavior of NiTi shape memory alloy. *J Biomed Mater Res*. 2000;51:685-693.
 16. Sapoval MR, Gaux JC, Long AL, et al. Transient periprosthetic thickening after covered-stent implantation in the iliac artery. *AJR Am J Roentgenol*. 1995;164:1271-1273.
 17. Stehbens WE. Observations on the development of mural thrombi in chronic experimental aneurysms in sheep. *Thromb Haemost*. 1997;78:952-957.
 18. Riepe G, Heintz C, Kaiser E, et al. What can we learn from explanted endovascular devices? *Eur J Vasc Endovasc Surg*. 2002;24:117-122.
 19. van Marrewijk CJ, Leurs LJ, Vallabhaneni SR, et al. Risk-adjusted outcome analysis of endovascular abdominal aortic aneurysm repair in a large population: how do stent-grafts compare? *J Endovasc Ther*. 2005;12:417-429.
 20. Trepanier C, Tabrizian M, Yahia LH, et al. Effect of modification of oxide layer on NiTi stent corrosion resistance. *J Biomed Mater Res*. 1998;43:433-440.
 21. Lerouge S, Guidoin R, Ashton T, et al. Nitinol self-deployable prostheses: variability in corrosion resistance. *Ann Chi Sci Mat*. 2004;29:41-52.
 22. Casas J, Zhao Q, Donovan M, et al. In vitro modulation of macrophage phenotype and inhibition of polymer degradation by dexamethasone in a human macrophage/Fe/stress system. *J Biomed Mater Res*. 1999;46:475-484.
 23. Malik N, Francis S, Holt C, et al. Apoptosis and cell proliferation after porcine coronary angioplasty. *Circulation*. 1998;98:1657-1665.
 24. Tomasek JJ, Gabbiani G, Hinz B, et al. Myofibroblasts and mechano-regulation of connective tissue remodelling. *Nat Rev Mol Cell Biol*. 2002;3:349-363.
 25. Schwartz RS, Huber KC, Murphy JG, et al. Restenosis and the proportional neointimal response to coronary artery injury: results in a porcine model. *J Am Coll Cardiol*. 1992;19:267-274.
 26. Jacob T, Ascher E, Hingorani A, et al. Initial steps in the unifying theory of the pathogenesis of artery aneurysms. *J Surg Res*. 2001;101:37-43.
 27. Rowe VL, Stevens SL, Reddick TT, et al. Vascular smooth muscle cell apoptosis in aneurysmal, occlusive, and normal human aortas. *J Vasc Surg*. 2000;31:567-576.
 28. Callow AD. Problems in the construction of a small diameter graft. *Int Angiol*. 1988;7:246-253.
 29. Lerouge S, Raymond J, Schloesser K, et al. Effect of radioactivity on stent-graft incorporation after endovascular treatment of aneurysms: an animal model. *J Biomed Mater Res (part A)*. 2006; in press.
 30. Upchurch GR. Gene therapy to treat aortic aneurysms: right goal, wrong strategy. *Circulation*. 2005;112:939-940.
 31. Allaire E, Muscatelli-Groux B, Guinault AM, et al. Vascular smooth muscle cell endovascular therapy stabilizes already developed aneurysms in a model of aortic injury elicited by inflammation and proteolysis. *Ann Surg*. 2004;239:417-427.