

● *Original Contribution*

REVIEW OF THE ASSESSMENT OF SINGLE LEVEL AND MULTILEVEL ARTERIAL OCCLUSIVE DISEASE IN LOWER LIMBS BY DUPLEX ULTRASOUND

LOUIS ALLARD,* GUY CLOUTIER,*[†] ZHENYU GUO,[‡] and LOUIS-GILLES DURAND*[†]

*Laboratoire de Génie Biomédical, IRCM, and [†]Département de Médecine, Université de Montréal, Montréal, Québec, Canada; and [‡]Department of Electrical Engineering, George Washington University, Washington, DC

(Received 18 December 1997; in final form 3 August 1998)

Abstract—The purpose of this article is to review the performance of duplex ultrasound scanning in assessing lower limb arterial disease with emphasis on patients with multisegmental occlusive lesions. Several studies have reported that duplex scanning can be as accurate as angiography to localize arterial stenoses. In spite of these promising results, there still remain some difficulties and controversies. Among them, it has been reported that multisegmental disease may affect the accuracy of duplex scanning. Indeed, some studies have indicated a lower sensitivity for detecting significant stenoses distal to severe or total occlusions. It also was demonstrated that second-order stenoses were detected with lower sensitivity compared to first-order stenoses. The main reason proposed to explain this lower sensitivity is that the highly reduced flow distal to occluded or highly stenotic segments increases the difficulty of detecting significant Doppler velocity changes in the distal or secondary stenoses. The intrinsic limitations of the peak systolic velocity ratio used as a classification criterion are presented. Finally, new and promising developments in power Doppler imaging and ultrasound contrast agents are discussed, because they may allow expansion of the capabilities of current ultrasound scanning systems and provide more accurate diagnosis of patients with multiple disease. © 1999 World Federation for Ultrasound in Medicine & Biology.

Key Words: Doppler ultrasound, Power mode, Arterial occlusive disease, Stenosis, Review.

INTRODUCTION

Two review articles covering the history of Doppler ultrasound for the diagnosis of peripheral vascular disease (Sigel 1998) and the current developments and applications in arterial ultrasound (Hoskins et al. 1998) were published recently. The present review constitutes a complement to those two articles and deals with the assessment of lower limb arterial disease with a specific emphasis on patients with multisegmental occlusive lesions.

According to Samson et al. (1985), the occurrence of combined aortoiliac and femoropopliteal disease is estimated to range between 20% and 69% of patients requiring lower limb revascularization. Compared to those with single level occlusive disease, patients with multilevel disease more often are male and older. They also have a higher incidence of diabetes, coronary and

cerebral arterial disease, and progression of lower limb arterial disease (Moneta et al. 1994; Samson et al. 1985).

Detecting the location and evaluating the severity of the lesions causing ischemia in the lower limb arteries of patients with combined aortoiliac and femoropopliteal disease is a difficult and important clinical problem. The ability to determine the hemodynamic effect of each lesion is essential before planning vascular surgical procedure or angioplasty. The most commonly used approach to treat these patients has been to carry out either a proximal reconstruction or angioplasty to improve inflow to the deep femoral artery, followed by a distal reconstruction, if indicated. This procedure is based on the observation that revascularization of the proximal segment usually improves perfusion of the lower leg by increasing flow through one of the distal arterial branches. Presently, contrast arteriography, which remains the standard method for investigating patients with arterial disease in most medical centers, is considered mandatory prior to arterial bypass surgery. However, risks (puncture site hematoma, arterial thrombi or em-

Address correspondence to: Louis-Gilles Durand, IRCM, 110 avenue des Pins ouest, Montréal, Québec, Canada, H2W 1R7.

Table 1. Doppler ultrasound versus angiography in classifying lower limb arterial stenoses in a five-class decision scheme.

Authors (yr)	Duplex scanning	No. of segments	Classification criteria	Percent of correct classification
Jager et al. (1985a)	Conventional	338	WC, SB, and PSV	76
Kohler et al. (1987)	Conventional	393	WC, SB, and PSV	69
Langsfeld et al. (1988)	Conventional	166	WC, SB, and PSV	55
Allard et al. (1994)	Conventional	642	WC, SB, and PSV	68

PSV = peak systolic velocity; SB = spectral broadening; WC = waveform contour.

boli, dye toxic reaction, and renal failure), interobserver variability, cost, and discomfort associated with this invasive procedure are major limitations. Another drawback is that, in practice, routine contrast studies generally include only a single plane view, which may fail to detect the arterial disease (especially in the aortoiliac segment) because plaques do not necessarily produce concentric area reduction. In addition, contrast medium may become so diluted in the presence of multisegmental disease that it may fail to opacify patent distal runoff vessels (Owen et al. 1992; Patel et al. 1988). These complications and limitations have stimulated the development of noninvasive methods to assess and follow up patients with peripheral vascular disease.

CONVENTIONAL DUPLEX ECHOGRAPHIC DOPPLER SCANNING

B-mode imaging provides access to the geometry of blood vessels and tissues. In arterial occlusive disease, the soft plaques and thrombi occluding the vessel have similar acoustic properties to those of blood and, thus, cannot be detected easily on the basis of B-mode imaging alone (Jager et al. 1985b). With the advent of duplex ultrasound systems, which combine real-time B-mode imaging and pulsed Doppler modality, measurement of blood flow velocity at specific sites within vessels became possible. The assessment of disease using this technique has been performed by visual interpretation of the pulsed Doppler blood flow spectra. Criteria based on the shape of the Doppler velocity envelope, the degree of spectral broadening, and the velocity increase within the stenosis have been proposed by Jager et al. (1985a) for quantifying arterial lesions in a multiclass decision scheme (0%, 1%–19%, 20%–49%, 50%–99%, and 100% diameter reduction). Based on these criteria, the results of four clinical studies in several arterial segments showed a percentage of correct classification ranging between 55% and 76% (Table 1) when compared to angiography (Allard et al. 1994; Jager et al. 1985a; Kohler et al. 1987; Langsfeld et al. 1988). To distinguish arterial stenoses <50% in diameter reduction from those \geq 50%, these four studies indicated a sensitivity

varying between 74% and 82%, and a specificity varying between 92% and 98% (Table 2). A computer analysis and pattern recognition system was developed based on these criteria, and small improvements in the classification performance were obtained (Allard et al. 1991; Guo et al. 1994).

COLOR DOPPLER FLOW IMAGING

Although conventional duplex scanning has been the preferred noninvasive method for lower limb applications, some limitations have restricted its acceptance. Among them, the most important are as follows: (1) the flow information is obtained only within the sample volume and not in the whole vessel; (2) the examination is time-consuming; and (3) the interpretation of the Doppler signal is complex (Berritt 1987). With the introduction of color Doppler flow imaging, many of these limitations were overcome, because it became possible to localize and identify more rapidly the vessels as well as to detect flow abnormalities caused by arterial disease. Such ultrasonic imaging systems are used widely today to locate noninvasively the lower limb arterial disease, although it is recognized that color Doppler imaging alone cannot replace Doppler spectral waveform analysis to grade arterial stenosis (Hatsukami et al. 1992; Polak 1995; Sacks 1992). Color Doppler imaging is useful for qualitative analysis of blood flow characteristics and vessel identification for Doppler sample volume positioning. Also, the location of the maximum blood velocity within a stenotic vessel can be identified more easily, resulting in more accurate velocity measurements. As shown in Table 2, sensitivity for detecting significant versus nonsignificant stenoses generally are improved by using color-assisted duplex sonography.

DOPPLER VELOCITY RATIO

Some studies (Leng et al. 1993; Ranke et al. 1992; Tessler et al. 1990) investigated the variability and reproducibility of measuring Doppler waveform characteristics used to grade lower limb arterial stenoses. It was shown that the peak systolic velocity, waveform shape,

Table 2. Range of sensitivity (%) and specificity (%) of Doppler ultrasound as compared to angiography for the detection of stenoses <50% and ≥50% diameter reduction in different arterial segments.

Authors (y)	Duplex scanning	Arterial segments (n)	Classification criteria	Range of sensitivity (mean sensitivity)	Range of specificity (mean specificity)
Jager et al. (1985a)	Conventional	Iliac to popliteal (7)	WC, SB and PSV	56–88 (77)	90–100 (98)
Kohler et al. (1987)	Conventional	Aorta to popliteal (6)	WC, SB and PSV	67–100 (82)	81–100 (92)
Langsfeld et al. (1988)	Conventional	Aorta to femoral (5)	WC, SB and PSV	N/A (82)	N/A (93)
Allard et al. (1994)	Conventional	Aorta to popliteal (7)	WC, SB and PSV	36–100 (74)	92–98 (96)
Legemate et al. (1991)	Conventional	Aorta to popliteal (9)	PSV ratio = 2.5	57–100 (84)	93–100 (96)
Sacks et al. (1992)	Conventional	Aorta to popliteal (8)	PSV ratio = 1.4	N/A (71) ^a	N/A (97) ^a
Ranke et al. (1992)	Conventional	Femoral (1)	PSV ratio = 2.4	87 (87)	94 (94)
de Smet et al. (1996)	Conventional	Aortoiliac (1)	PSV ratio = 2.8	86 (86)	84 (84)
Cossmann et al. (1989)	Color	Iliac to infrapopliteal (8)	PSV and PSV ratio = 2.0	50–94 (87)	94–100 (99)
Polak et al. (1990)	Color	Femoral to popliteal (7)	PSV ratio = 2.0	25–100 (88)	81–100 (95)
Moneta et al. (1992)	Color	Iliac to popliteal (5)	WC, PSV, and PSV ratio = 2.0	67–89 (N/A)	97–99 (N/A)
Leng et al. (1993)	Color	Femoropopliteal (1)	PSV ratio = 3.0	70 (70)	96 (96)
Bergamini et al. (1995)	Color	Femoral to infrapopliteal (6)	PSV ratio = 2.0	25–93 (80)	90–100 (95)
Pinto et al. (1996)	Color	Iliac to infrapopliteal (9)	PSV ratio = 2.0	88–96 (94)	85–98 (93)
Sensier et al. (1996a)	Color	Aorta to infrapopliteal (13)	PSV ratio = 2.0	N/A (69)	N/A (96)

n = number of arterial segments by limb considered in the classification.

^a Excluding occlusions.

WC = waveform contour. SB = spectral broadening; PSV = peak systolic velocity; N/A = data not available.

and spectral broadening were relatively poor predictors of the degree of stenosis. This result can be explained by the fact that different factors can affect the estimation of these criteria and reduce their clinical validity. These factors are related to (1) hemodynamic factors, such as cardiac function, peripheral vascular resistance, and status of proximal and distal segments, and (2) factors attributable to the equipment and operator, such as the dimension of the sample volume, its location within the arterial lumen, gain setting, and other instrumentation factors (Gill 1985; Jones 1993; Knox et al. 1982). For these reasons, recent studies have placed more emphasis on the relative changes in the peak systolic velocity (PSV). The PSV ratio (intra-stenotic PSV divided by the pre- or poststenotic PSV) has been evaluated more specifically. Initially suggested to grade carotid stenoses (Keagy et al. 1982; Rittgers et al. 1983; Spencer and Reid 1979), it was found that its use to assess lower limb arterial occlusive disease allowed minimization of the variability in PSV measurements obtained from different arterial segments and from different patients. Some theoretical considerations to be discussed following are, however, important when using this index.

By definition, the flow through a vessel is simply the product of the average velocity \bar{v} and the cross-sectional area A . If the flow volume remains constant through an arterial segment containing a stenosis, the following theoretical relationship between the ratio of the average velocities and the ratio of the cross-sectional areas can be derived:

$$\bar{v}_2/\bar{v}_1 = A_1/A_2$$

where \bar{v}_1 and A_1 represent the average velocity across the arterial lumen and the cross-sectional area proximal or distal to the stenosis (reference site), respectively, and \bar{v}_2 and A_2 are the same quantities measured within the stenosis. For simplification, the blood velocity averaged in space and in time generally is replaced by the PSV, which is the maximum Doppler velocity measured within the stenosis at peak systole. It is clear that this substitution can introduce some bias and a flow characteristic dependence. More precisely, the following conditions, not always emphasized in the literature, must be respected between the two recording sites for an accurate and reproducible evaluation of a stenosis using the PSV ratio: (1) the flow rate must be the same at the two recording sites (no collateral branch); (2) the vessel diameter at the reference site must be the same as the diameter of the nonobstructed section of the segment under evaluation (no tapering); (3) the reference site must be located away from any arterial stenosis; (4) the Doppler angle must be the same for the two velocity measurements; and (5) the velocity profile across the vessel at peak systole must be the same at the two recording sites.

In practice, all these conditions are hardly respected, especially in cases where the stenosis is localized at the origin of the arterial segment or in situations involving multisegmental disease. Nevertheless, different studies investigated *in vitro* (Whyman et al. 1993) and *in vivo* (Bergamini et al. 1995; Cossmann et al. 1989; de Smet et al. 1996; Legemate et al. 1991; Leng et al. 1993; Moneta et al. 1992; Mulligan et al. 1991; Polak et al. 1990; Ranke et al. 1992; Sacks et al. 1992) the

Table 3. Sensitivity of duplex criteria as compared to angiography for the detection of first- and second-order stenoses ($\geq 50\%$ diameter reductions) or in the presence and absence of adjacent disease.

Authors (y)	Duplex scanning	Classification criteria	Arterial segment status	Sensitivity (%)
Allard et al. (1994)	Conventional	WC, SB, and PSV	Without adjacent disease	80
Sack et al. (1992)	Conventional	PSV	With adjacent disease	66
			First-order stenoses	87 ^a
			Second-order stenoses	56 ^a
			PSV ratio = 1.4	82 ^a
Bergamini et al. (1995)	Color	PSV ratio = 2.0	Second-order stenoses	62 ^a
			First-order stenoses	78 ^a
Sensier et al. (1996a)	Color	PSV ratio = 2.0	Second-order stenoses	13 ^a
			Without adjacent disease	73
			With adjacent disease	85

^a Excluding occlusions.

PSV = peak systolic velocity; SB = spectral broadening; WC = waveform contour.

accuracy and the reproducibility of the PSV ratio for grading lower limb arterial stenoses. Results from the *in vitro* model indicated that the variability in measuring the PSV ratio generally was low and correlated very well with the degree of stenosis ($R^2 = 0.996$). The theoretical model expressed by eqn. (1) was, however, not directly applicable in this study, probably because one or several of the previous conditions were not fulfilled. In clinical situations, results indicated that the PSV ratio could distinguish severe from minor stenoses with a sensitivity ranging between 67% and 95%, and a specificity between 84% and 99% (Table 2). In these studies, a ratio between 1.4 and 3 was used as a cutoff value. Using this index, the determination of the degree of obstruction in a multiclass decision scheme was shown to be less reliable (Leng et al. 1993).

EVALUATION OF PATIENTS WITH MULTIPLE ARTERIAL STENOSES

Multisegmental disease generally is defined by the presence of a severe stenosis in both aortoiliac (inflow disease) and femoropopliteal (outflow disease) tracts. When considering individual arterial segments, multisegmental disease may refer to the presence of a severe stenosis in adjacent segments (*e.g.*, aorta and iliac artery) (Allard et al. 1994). It also has been defined in terms of the presence of first- and second-order stenoses. Sacks et al. (1992) described a first-order stenosis as the first or only significantly diseased segment within a leg and a second-order stenosis as the subsequent significantly diseased segment within the same leg. These terms do not refer to sequential stenoses within the same segment, because it is clinically more relevant to focus on the most severe lesion. Very few *in vivo* studies have reported detailed observations and results on the ability of Doppler spectral analysis to grade arterial disease with multisegmental lesions.

In a study using conventional duplex scanning, Jager et al. (1985a) mentioned that the PSV and spectral broadening criteria defined for a single stenosis may be used in patients with multisegmental disease. This study also reported that the presence of multisegmental disease did not influence the performance of the technique, although no specific result was presented to confirm this conclusion. A similar conclusion was supported by Kohler et al. (1987), although they reported a lower sensitivity for detecting hemodynamically significant stenoses in low-flow segments distal to total occlusions.

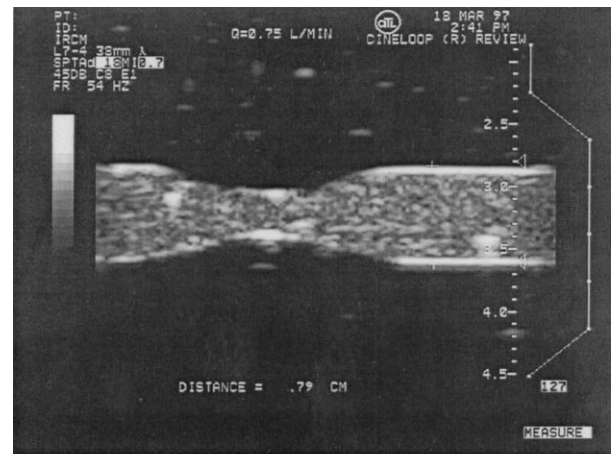
From a retrospective study using conventional duplex scanning and the criteria of Jager et al. (1985a); Allard et al. (1994) demonstrated that the accuracy for detecting a 0–49% versus a 50%–100% lesion in the aortoiliac tract was always higher than 90%, except when inflow and outflow disease were present. In this case, the accuracy was reduced to 67%. When evaluating each arterial segment, results indicated that the sensitivity ranged between 36% and 100%. The best sensitivity was obtained for the aorta, whereas the worst sensitivities were associated with the common femoral, deep femoral, and popliteal arteries. The important point here is that, in this last segment, 10 of 12 misclassifications involved the presence of proximal disease. It was thus concluded that the criteria related to the shape of the Doppler velocity envelope, the amount of spectral broadening, and the PSVs were not reproducible enough to allow an objective and accurate evaluation of peripheral arterial stenoses in lower limbs with multisegmental disease (Table 3).

As previously mentioned, the PSV ratio appears to be a simple and accurate predictor of severe stenoses. However, little is known regarding its discriminant power in situations involving multiple stenoses. A study by Ranke et al. (1992) showed that the presence of multisegmental disease did not affect their overall re-

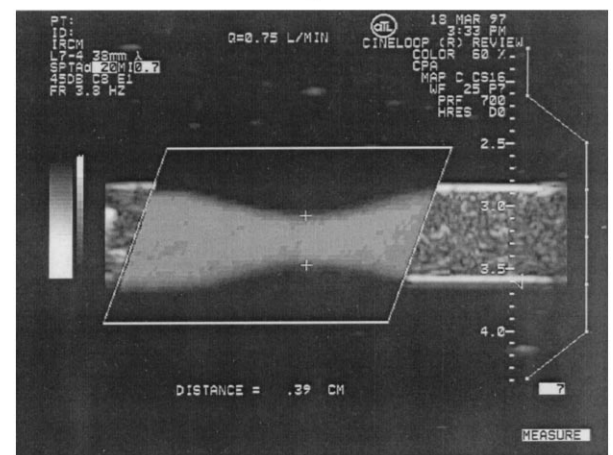
sults. Indeed, when evaluating the correlation of the PSV ratio with the angiographic diameter reduction, they found that the correlation for cases involving multisegmental disease ($r = 0.92$) and stenoses at the origin of a segment ($r = 0.89$) was not significantly different when compared to the overall segment analyzed ($r = 0.93$). In a recent study on 1106 arterial segments, Sensier *et al.* (1996a) showed that color duplex scanning of the lower limb was not adversely affected by adjacent disease (Table 3). Indeed, the kappa value between duplex ultrasound and arteriography was higher in the presence of neighboring disease than for isolated disease ($\kappa = 0.78$ vs. 0.63). As will be presented, other studies addressing this controversial issue provided conclusions, or at least information, suggesting that the presence of multisegmental disease can affect the accuracy of duplex scanning.

From an *in vitro* model, Allard *et al.* (1995) demonstrated that the presence of a proximal and/or a distal stenosis close to the one under study had an important effect on the PSV ratio. The results indicated that it can be difficult correctly to quantify a stenosis due to the absence of any reference site for measuring the pre- or poststenotic velocity. These conclusions, drawn from a simplified model probably can be extended to more realistic conditions involving stenoses located on different segments, as found in the lower limb arterial tree.

Using the PSV ratio, Sacks *et al.* (1992) reported a lower sensitivity (62% vs. 82%) when detecting second-order stenoses compared to first-order stenoses (Table 3). An important reduction of the sensitivity (87% to 56%) was obtained when using the PSV alone instead of the PSV ratio as the diagnostic criterion. Results presented by Moneta *et al.* (1992) indicated that the performance of the ultrasonic technique based on the PSV ratio and Doppler waveform contour decreased when studying more distal arteries. In fact, their best result was obtained over the iliac artery (sensitivity of 89% for detecting significant stenoses), whereas the worst performance was measured over the popliteal artery (sensitivity of 67%). It can be speculated, from the distribution of the occlusive disease provided by the authors, that the low sensitivity in the popliteal artery probably resulted from the high occurrence (43%) of significant stenoses in the superficial femoral artery. For the subgroup of limbs with a low occurrence (4%) of disease in the superficial femoral artery, results indicated a sensitivity of 100% for detecting severe stenoses in the popliteal artery. Legemate *et al.* (1991) postulated that the PSV ratio would not be affected by multisegmental disease, although they observed lower positive predictive values and sensitivities in detecting significant stenoses for the common and deep femoral and popliteal arteries. For the nine occluded popliteal segments, five cases of false-positive



a



b

Fig. 1. (a) B-mode and (b) power Doppler images of a wall-less agar phantom with a 80% area reduction stenosis (normal vessel diameter of 7.96 mm). The true diameter of the stenosis (3.56 mm) was estimated to be 3.9 mm by power Doppler imaging. These images were generated under steady flow (flow rate of 12.5 mL/s) using sephadex particles suspended in a solution of glycerol and water as blood-mimicking fluid.

Doppler examinations were reported and were explained by the presence of occlusions in the superficial femoral segment. Results by Polak *et al.* (1990) indicated that, among the seven false-negative Doppler examinations obtained when detecting significant stenoses, four were distal to occluded or highly stenotic segments. Finally, using the PSV ratio, Bergamini *et al.* (1995) detected 78% of the first-order stenoses compared to only 13% of the second-order stenoses (Table 3). As a consequence, they observed a markedly lower sensitivity in the popliteal and tibioperoneal trunk levels.

Due to these controversial observations on the performance of duplex scanning and color Doppler flow imaging in the presence of multisegmental disease, it is suggested to pay particular attention when clinically ap-

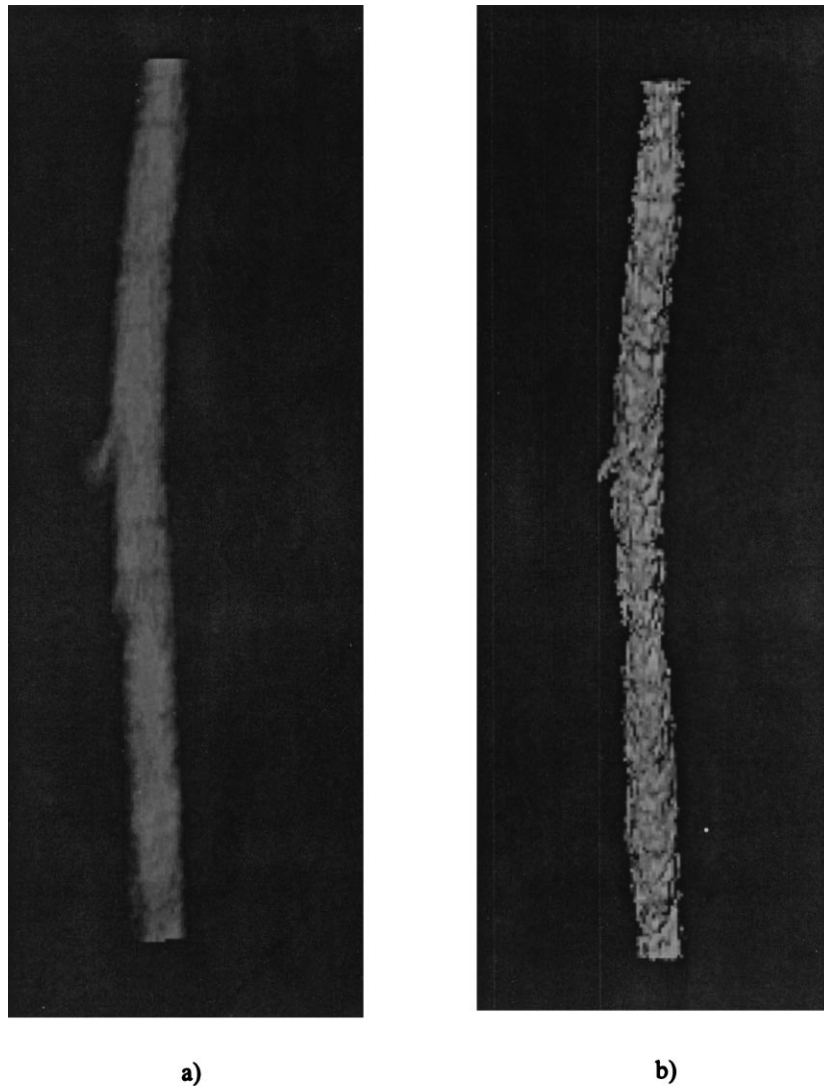


Fig. 2. Three-dimensional power Doppler images of a superficial femoral artery of a normal subject displayed over a length of 9.4 cm using (a) texture mapping and (b) surface rendering techniques.

plying the PSV ratio to patients with multisegmental lower limb disease. It also is believed that additional basic and clinical work is required to improve the performance of the ultrasonic approach for the assessment of lower limb arterial disease.

NEW PERSPECTIVE

Current commercial Doppler imaging systems can provide direct functional information from the measurement of Doppler blood flow velocity and indirect anatomical information from the Doppler velocity ratio (eqn. (1)). In the future, it may be possible that vessel narrowing could be determined more accurately by using power Doppler imaging, because this new technique has an

increased sensitivity to low-flow conditions and can characterize directly the geometry of blood vessels (Macsweney et al. 1996; Rubin and Adler 1993; Rubin et al. 1994). Recently, power Doppler imaging has been evaluated using wall-less agar phantoms and blood-mimicking fluid to quantify vascular stenoses (Guo and Fenster 1996; Guo et al. 1998). Figure 1 shows B-mode and power Doppler images of a wall-less agar phantom with a 80% area reduction stenosis. It can be seen that power Doppler imaging can provide an accurate representation of the flow lumen. Results also indicated that the presence of proximal and distal stenoses appeared to have no effect on the quantification of the central stenosis. Less dependent on flow characteristics, this modality may not

be affected by the presence of multiple stenoses and thus could provide a significant benefit for the patient.

Another promising avenue in Doppler imaging is the use of a three-dimensional (3D) representation of the arterial lumen. Figure 2 shows 3D power Doppler images of a superficial femoral artery of a normal subject, demonstrating that power Doppler imaging can generate very good angiographic images, allowing the diagnosis of arterial occlusive disease. Although 3D power Doppler imaging is at an early stage of development, it is possible that a complete 3D view of the arterial and venous flow field of the lower limbs, including the collaterals, may be obtained. Doppler ultrasonic systems allowing 3D representation of both functional (Doppler velocity) and anatomical (Doppler power) images of the lower limb arterial segments should improve the assessment of the peripheral arterial system.

Finally, significant improvement in the evaluation of lower limb arterial disease is anticipated by the use of ultrasound contrast agents (Langholz *et al.* 1996). Indeed, with the strong echo enhancement provided by the contrast agents, it could be easier to detect the Doppler signals and to get a more accurate representation of the blood flow in deep vessels, in patients with arterial wall calcification, and in patients with multiple stenoses and low blood flow velocity. Ultrasound contrast agents may improve the examination of obese patients or patients with gaseous abdomen where interrogation of the aortoiliac segment is difficult (Bodily *et al.* 1996; Cossman *et al.* 1989; Mulligan *et al.* 1991; Sacks *et al.* 1992).

CONCLUSION

With continuing improvements in Doppler ultrasound technology, it is expected that patients with lower limb arterial disease would be evaluated more accurately and less frequently subjected to contrast angiography. Initially used for the assessment of aortoiliac and femoropopliteal arteries, duplex scanning has become a valuable tool for use in the infrapopliteal segment (Cossman *et al.* 1989; Hatsukami *et al.* 1992; Karacagil *et al.* 1996; Larch *et al.* 1997; Moneta *et al.* 1992; Sensier *et al.* 1996b). Visualization of the complete arterial tree of the lower limb from the aorta to the foot arteries is justified by improvements in vascular surgery procedures allowing bypass grafting to very small distal arteries. The evaluation of infrapopliteal arteries is important to identify a patent runoff vessel suitable for the bypass procedure. Color Doppler imaging also is helpful in the surveillance of arterial bypass grafts (Greene *et al.* 1990) and after percutaneous transluminal angioplasty (Spijkerboer *et al.* 1996; Tielbeek *et al.* 1996; Vroegindewij *et al.* 1995) to detect the development of restenosis at the site of intervention.

With the increasing use and confidence in duplex scanning as a screening tool, diagnostic angiography before a therapeutic intervention may not be required in some patients, because no additional information is provided by angiography on the treatment strategy. Recent studies have demonstrated that the selection of patients with isolated, short segment lesions for transluminal angioplasty can be made on the basis of the duplex scanning results alone (Edwards *et al.* 1991; Elsman *et al.* 1995; 1996; Katzenschlager *et al.* 1996). In a logical extension, Pemberton *et al.* (1996) demonstrated that a wide range of revascularizing procedures also could be performed safely based on findings of duplex scanning alone. A similar conclusion was obtained by Bodily *et al.* (1996) concerning aortoiliac reconstruction when a totally occluded aorta or iliac artery was identified.

Acknowledgements—The authors gratefully acknowledge the Fondation des Maladies du Cœur du Québec, the Medical Research Council of Canada, and the Fonds de la Recherche en Santé du Québec for financial support of the authors' projects, whose results are presented in this article. Acknowledgments are also addressed to Dr. Helen Routh of Advanced Technology Laboratories for loaning us the HDI Ultramark 9 system used to obtain Figs. 1 and 2, to Dr. Aaron Fenster, Imaging Research Laboratory, John P. Robarts Research Institute and Life Imaging System, London, Ontario, for providing the 3D imaging software, and to Mrs. Francine Tardif for her technical assistance in the preparation of Fig. 2.

REFERENCES

- Allard L, Cloutier G, Durand LG. Doppler velocity ratio measurements evaluated in a phantom model of multiple arterial disease. *Ultrasound Med Biol* 1995;21:471–480.
- Allard L, Cloutier G, Durand LG, Roederer GO, Langlois YE. Limitations of ultrasonic duplex scanning for diagnosing lower limb arterial stenoses in the presence of adjacent segment disease. *J Vasc Surg* 1994;19:650–657.
- Allard L, Langlois YE, Durand LG, *et al.* Computer analysis and pattern recognition of Doppler blood flow spectra for disease classification in the lower limb arteries. *Ultrasound Med Biol* 1991;17:211–223.
- Bergamini TM, Tatum CM, Marshall C, Hall-Disselkamp B, Richardson JD. Effect of multilevel sequential stenosis on lower extremity arterial duplex scanning. *Am J Surg* 1995;169:564–566.
- Berritt CRB. Doppler color flow imaging. *J Clin Ultrasound* 1987;15:591–597.
- Bodily K, Buttorff J, Nordesgaard A, Osborne RJ. Aorto-Iliac reconstruction without arteriography. *Am J Surg* 1996;171:505–507.
- Cossman DV, Ellison JE, Willis RVT, *et al.* Comparison of contrast arteriography to arterial mapping with color-flow duplex imaging in the lower extremities. *J Vasc Surg* 1989;10:522–529.
- de Smet AEA, Ermers EJM, Kitslaar PJEHM. Duplex velocity characteristics of aortoiliac stenoses. *J Vasc Surg* 1996;23:628–636.
- Edwards JM, Coldwell DM, Goldman ML, Strandness DE Jr. The role of duplex scanning in the selection of patients for transluminal angioplasty. *J Vasc Surg* 1991;13:69–74.
- Elsman BHP, Legemate DA, van der Heijden FWHM, *et al.* Impact of ultrasonographic duplex scanning on therapeutic decision making in lower-limb arterial disease. *Br J Surg* 1995;82:630–633.
- Elsman BHP, Legemate DA, van der Heyden FWHM, *et al.* The use of color-coded duplex scanning in the selection of patients with lower extremity arterial disease for percutaneous transluminal angioplasty: A prospective study. *Cardiovasc Intervent Radiol* 1996;19:313–316.

- Gill RW. Measurement of blood flow by ultrasound accuracy and sources of error. *Ultrasound Med Biol* 1985;11:625-641.
- Greene RM, McNamara J, Ouriel K, DeWeese JA. Comparison of infrainguinal graft surveillance techniques. *J Vasc Surg* 1990;11:207-215.
- Guo Z, Durand LG, Allard L, Cloutier G, Fenster A. In vitro evaluation of multiple arterial stenoses using three-dimensional power Doppler angiography. *J Vasc Surg* 1998;27:681-688.
- Guo Z, Durand LG, Allard L, Cloutier G, Lee HC. Classification of lower limb stenoses from Doppler blood flow signal analysis with time-frequency representation and pattern recognition techniques. *Ultrasound Med Biol* 1994;20:335-346.
- Guo Z, Fenster A. Three-dimensional power Doppler imaging: A phantom study to quantify vessels stenosis. *Ultrasound Med Biol* 1996;22:1059-1069.
- Hatsukami TS, Primozich JF, Zierler RE, Harley JD, Strandness DE Jr. Color Doppler imaging of infrainguinal arterial occlusive disease. *J Vasc Surg* 1992;16:527-533.
- Hoskins PR, Fish PJ, McDicken WN, Moran C. Developments in cardiovascular ultrasound. Part 2: arterial applications. *Med Biol Eng Comput* 1998;36:259-269.
- Jager KA, Phillips DJ, Martin RL, et al. Noninvasive mapping of lower limb arterial lesions. *Ultrasound Med Biol* 1985a;11:515-521.
- Jager KA, Ricketts HJ, Strandness DE Jr. Duplex scanning for the evaluation of lower limb arterial disease. In: Bernstein EF, ed. *Noninvasive diagnostic techniques in vascular disease*. St. Louis: CV Mosby, 1985b:619-631.
- Jones SA. Fundamental sources of error and spectral broadening in Doppler ultrasound signals. *CRC Crit Rev Biomed Eng* 1993;21:399-483.
- Karacagil S, Löfberg AM, Granbo A, Lörelus LE, Bergqvist D. Value of Duplex scanning in evaluation of crural and foot arteries in limbs with severe lower limb ischaemia—A prospective comparison with angiography. *Eur J Vasc Endovasc Surg* 1996;12:300-303.
- Katzenschlager R, Ahmadi A, Minar E, et al. Femoropopliteal artery: Initial and 6-month results of color Duplex US-guided percutaneous transluminal angioplasty. *Radiology* 1996;199:331-334.
- Keagy BA, Pharr WF, Thomas D, Bowles DE. Evaluation of the peak frequency ratio (PFR) measurement in the detection of internal carotid artery stenosis. *J Clin Ultrasound* 1982;10:109-112.
- Knox RA, Phillips DJ, Breslau PJ, et al. Empirical findings relating sample volume size to diagnostic accuracy in pulsed Doppler cerebrovascular studies. *J Clin Ultrasound* 1982;10:227-232.
- Kohler TR, Nance DR, Cramer MM, Vandenburghe N, Strandness DE Jr. Duplex scanning for diagnosis of aortoiliac and femoropopliteal disease: A prospective study. *Circulation* 1987;76:1074-1080.
- Langholz J, Schlieff R, Schurmann R, Wanke M, Heidrich H. Contrast enhancement in leg vessels. *Clin Radiol* 1996;51:31-34.
- Langsfeld M, Nepute J, Hershey FB, et al. The use of deep duplex scanning to predict hemodynamically significant aortoiliac stenoses. *J Vasc Surg* 1988;7:395-399.
- Larch E, Minar E, Ahmadi R, et al. Value of color duplex sonography for evaluation of tibioperoneal arteries in patients with femoropopliteal obstruction: A prospective comparison with anterograde intraarterial digital subtraction angiography. *J Vasc Surg* 1997;25:629-636.
- Legemate DA, Teeuwen C, Hoeneveld H, Ackerstaff RGA, Eikelboom BC. Spectral analysis criteria in duplex scanning of aortoiliac and femoropopliteal arterial disease. *Ultrasound Med Biol* 1991;17:769-776.
- Leng GC, Whyman MR, Donnan PT, et al. Accuracy and reproducibility of duplex ultrasonography in grading femoropopliteal stenoses. *J Vasc Surg* 1993;17:510-517.
- Macsweney JE, Cosgrove DO, Arenson J. Colour Doppler energy (power) mode ultrasound. *Clin Radiol* 1996;51:387-390.
- Moneta GL, Yeager RA, Antonovic R, et al. Accuracy of lower extremity arterial duplex mapping. *J Vasc Surg* 1992;15:275-284.
- Moneta GL, Yeager RA, Taylor LM, Porter JM. Hemodynamic assessment of combined aortoiliac/femoropopliteal occlusive disease and selection of single or multilevel revascularization. *Semin Vasc Surg* 1994;7:3-10.
- Mulligan SA, Matsuda T, Lanzer P, et al. Peripheral arterial occlusive disease: Prospective comparison of MR angiography and color duplex US with conventional angiography. *Radiology* 1991;178:695-700.
- Owen RS, Carpenter JP, Baum RAF, Perloff LJ, Cope C. Magnetic resonance imaging of angiographically occult runoff vessels in peripheral arterial occlusive disease. *N Engl J Med* 1992;326:1577-1581.
- Patel KR, Semel L, Clauss RH. Extended reconstruction rate for limb salvage with intraoperative prereconstruction angiography. *J Vasc Surg* 1988;7:531-537.
- Pemberton M, Nydahi S, Hartshorne T, et al. Can lower limb vascular reconstruction be based on colour duplex imaging alone? *Eur J Vasc Endovasc Surg* 1996;12:452-454.
- Pinto F, Lencioni R, Napoli V, Petrucci R, Vignali C, Armilotta N, and Bartolozzi C. Peripheral ischemic occlusive arterial disease: Comparison of color Doppler sonography and angiography. *J Ultrasound Med* 1996;15:697-704.
- Polak JF. Peripheral arterial disease. Evaluation with color flow and Duplex sonography. *Radiol Clin North Am* 1995;33:71-90.
- Polak JF, Karmel MI, Mannick JA, et al. Determination of the extent of lower-extremity peripheral arterial disease with color-assisted duplex sonography: Comparison with angiography. *AJR* 1990;155:1085-1089.
- Ranke C, Creutzig A, Alexander K. Duplex scanning of the peripheral arteries: Correlation of the peak velocity ratio with angiographic diameter reduction. *Ultrasound Med Biol* 1992;18:433-440.
- Ritters SE, Thornhill BM, Barnes RW. Quantitative analysis of carotid artery Doppler spectral waveforms: Diagnostic value of parameters. *Ultrasound Med Biol* 1983;9:255-264.
- Rubin JM, Adler RS. Power Doppler expands standard color capability. *Diagn Imaging* 1993;66-69.
- Rubin JM, Bude RO, Carson PL, Bree RL, Adler RS. Power Doppler US: A potentially useful alternative to mean frequency-based color Doppler US. *Radiology* 1994;190:853-856.
- Sacks D. Peripheral arterial duplex ultrasonography. *Semin Roentgenol* 1992;XXVII:28-38.
- Sacks D, Robinson ML, Marinelli DL, Perlmutter GS. Peripheral arterial Doppler ultrasonography: Diagnostic criteria. *J Ultrasound Med* 1992;11:95-103.
- Samson RH, Scher LA, Veith FJ. Combined segment arterial disease. *Surgery* 1985;97:385-396.
- Sensier Y, Hartshorne T, Trush A, et al. The effect of adjacent segment disease on the accuracy of colour duplex scanning for the diagnosis of lower limb arterial disease. *Eur J Vasc Endovasc Surg* 1996a;12:238-242.
- Sensier Y, Hartshorne T, Trush A, et al. A prospective comparison of lower limb colour-coded duplex scanning with arteriography. *Eur J Vasc Endovasc Surg* 1996b;11:170-175.
- Sigel B. A brief history of Doppler ultrasound in the diagnosis of peripheral vascular disease. *Ultrasound Med Biol* 1998;24:169-176.
- Spencer MP, Reid JM. Quantitation of carotid stenosis with continuous-wave (C-W) Doppler ultrasound. *Stroke* 1979;10:326-330.
- Spijkerboer AM, Nass PC, de Valois JC, et al. Iliac artery stenoses after percutaneous transluminal angioplasty: Follow-up with duplex ultrasonography. *J Vasc Surg* 1996;23:691-697.
- Tessler FN, Kimme-Smith C, Sutherland ML, et al. Inter- and intra-observer variability of Doppler peak velocity measurements: An in-vitro study. *Ultrasound Med Biol* 1990;16:653-657.
- Tielbeek AV, Rietjens E, Buth J, Broeindewij D, Schol FPG. The value of Duplex surveillance after endovascular intervention for femoropopliteal obstructive disease. *Eur J Vasc Endovasc Surg* 1996;12:145-150.
- Vroegindewij D, Tielbeek AV, Buth J, et al. Directional atherectomy versus balloon angioplasty in segmental femoropopliteal artery disease: Two-year follow-up with color flow duplex scanning. *J Vasc Surg* 1995;21:255-269.
- Whyman MR, Hoskins PR, Leng GC, et al. Accuracy and reproducibility of duplex ultrasound imaging in a phantom model of femoral artery stenosis. *J Vasc Surg* 1993;17:524-530.